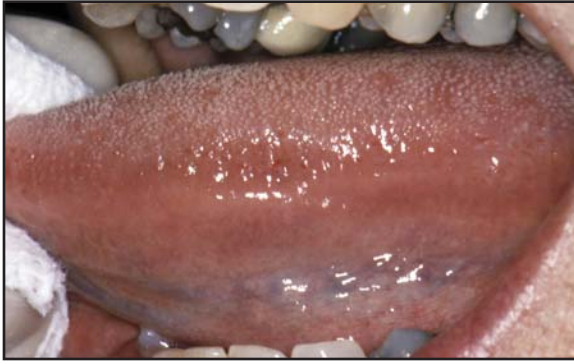
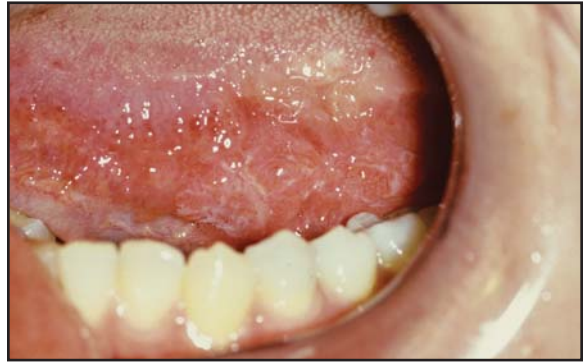
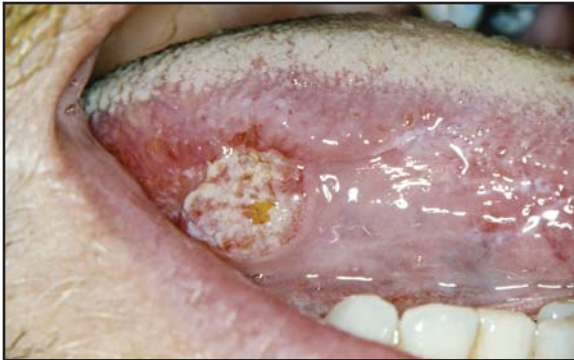SCREENING FOR ORAL CANCER



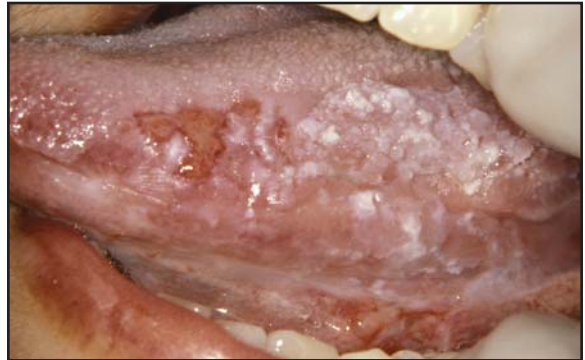Normal lateral tongue
Correct technique for visualization of lateral tongue.



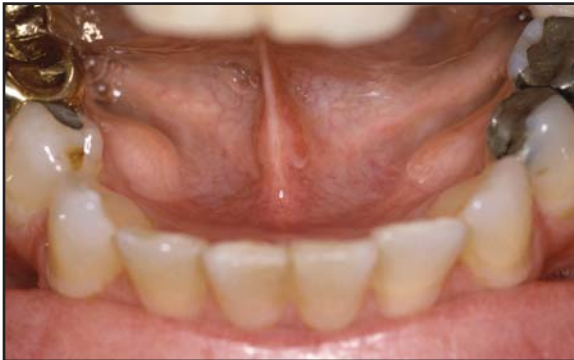Carcinoma-in-situ
Subtle clinical leukoplakia in a 31-year-old female with no risk factors for squamous cell carcinoma.



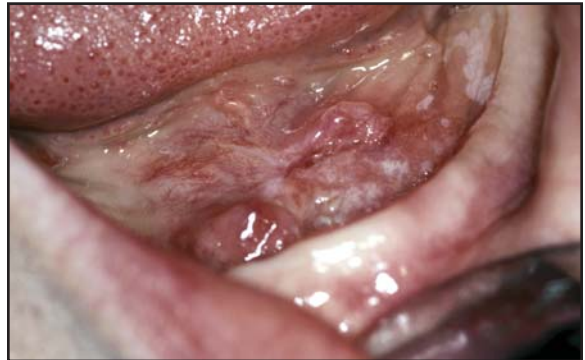Squamous cell carcinoma
Persistent asymptomatic ulceration in a 32-year-old male with no risk factors for squamous cell carcinoma.



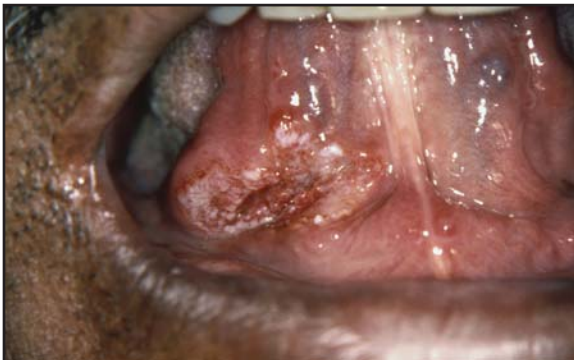Squamous cell carcinoma
Mixed erythroplakia-leukoplakia in a female with a history of tobacco use.



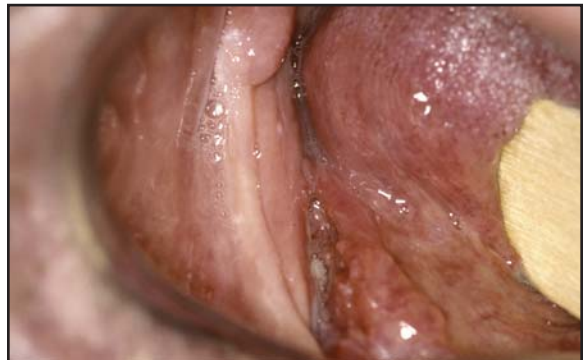Normal floor of mouth with bilateral mandibular tori (exostoses)



Squamous cell carcinoma
Mixed asymptomatic erythroplakia-leukoplakia in a 55-year-old female with history of tobacco and alcohol abuse.

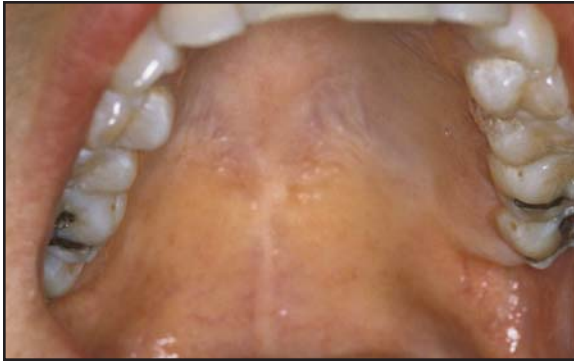


Squamous cell carcinoma
Ulceration with surrounding leukoplakia in a 63-year-old male with a history of tobacco and alcohol abuse.

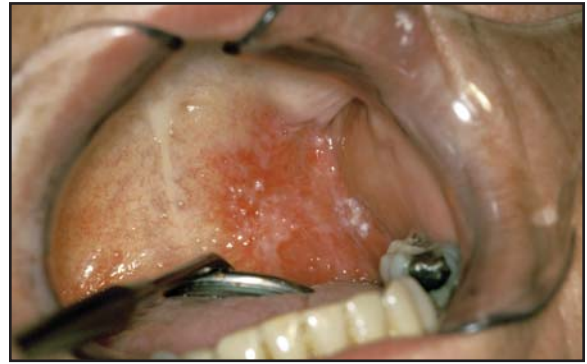

Squamous cell carcinoma
Ulceration on floor of mouth in edentulous patient, initially misinterpreted as denture irritation.

SCREENING FOR ORAL CANCER

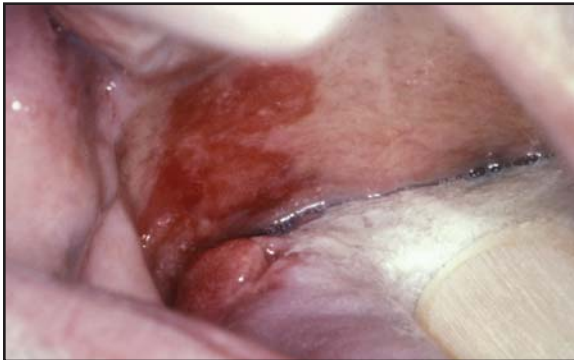

Normal hard and soft palate



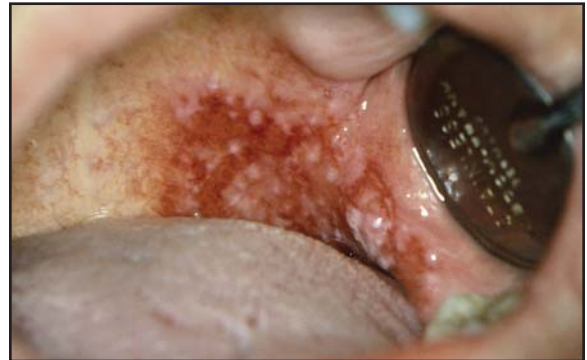Squamous cell carcinoma

Asymptomatic erythroplakia-leukoplakia in a 45-year old female with a history of tobacco and alcohol abuse.



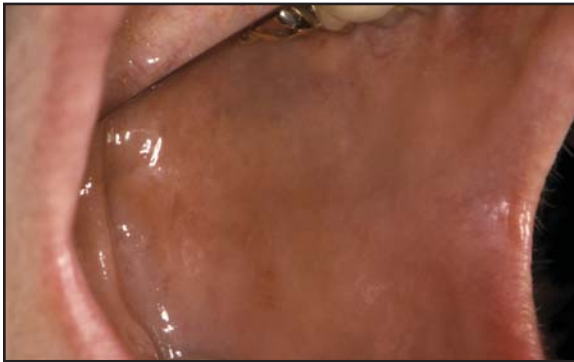Squamous cell carcinoma

Erythroplakic lesion of palate and posterior lateral tongue discovered on routine dental exam in a 60-year-old male with history of tobacco use.

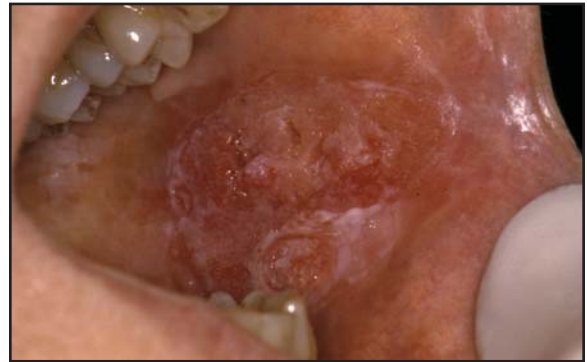

Squamous cell carcinoma

Asymptomatic, pebbly erythroplakia-leukoplakia with ulceration. Lesions with this appearance are commonly misinterpreted as a fungus infection.

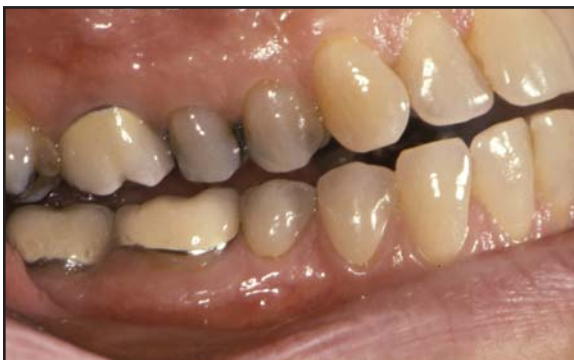

Normal buccal mucosa

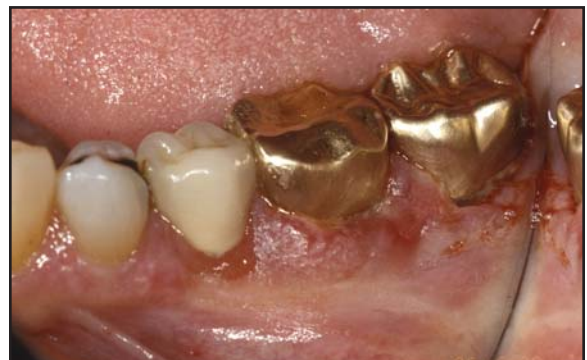

Squamous cell carcinoma

Slightly raised erythroplakia-leukoplakia in a 59-year-old female with history of tobacco use.



Normal gingiva



Squamous cell carcinoma

Mixed erythroplakia-leukoplakia erroneously treated as lichen planus prior to biopsy.