
DISEASES OF BONE

This study set deals with diseases of bone and is divided into three sections. The first section deals with three variants of normal that are often mistakenly diagnosed as diseases. Section II covers non-neoplastic bone diseases and Section III discusses bone tumors.

Most of these diseases favor youth; florid osseous dysplasia, Paget disease, chondrosarcoma and myeloma are exceptions. Although several conditions are inheritable, the cause of most of these diseases is unknown.

Primary diseases of bone are uncommon compared to other organ systems. Pulmonary, gastrointestinal, and genitourinary diseases far outrank skeletal diseases as causes of human morbidity and mortality. This does not diminish their importance, however.

No attempt is made to cover all diseases. In composing the list of conditions to include in this set, we have been guided by two considerations: 1) is the disease common enough that students of dentistry should know it, and 2) do questions concerning the disease appear often on National Board examinations?

INDEX

1. "Pseudo-diseases" easily mistaken for real diseases
 - a. Bone marrow defect
 - b. Osteosclerosis
 - c. Submandibular salivary gland defect
 - d. Subpontic osseous hyperplasia
 - e. Pseudocyst of the maxillary sinus
2. Non-neoplastic diseases of bone
 - a. Osteogenesis imperfecta
 - b. Osteopetrosis
 - c. Paget disease of bone
 - d. Fibrous dysplasia
 - e. Cherubism
 - f. Florid osseous dysplasia
3. Bone tumors
 - a. Central giant cell reparative granuloma
 - b. Ossifying and cementifying fibroma
 - c. Ewing sarcoma
 - d. Osteogenic sarcoma
 - e. Chondrosarcoma
 - f. Multiple myeloma
 - g. Histiocytosis X
(Langerhans' cell granulomatosis)

SECTION I

Pseudo-Diseases

BONE MARROW DEFECT

FIGURES 1-4

(Also, osteoporotic bone marrow defect, hematopoietic bone marrow defect)

The osteoporotic bone marrow defect is a variant of normal but is often mistakenly diagnosed as abnormal. There are usually no clinical signs nor symptoms.

RADIOGRAPHIC FEATURES: The bone marrow defect appears as a radiolucent area in bone. Although they occur in all areas of the jaws, the most common location is the molar and premolar region of the mandible. One study reports that 23% of marrow defects occur in old extraction sites. Women are more often affected than men and the median age is 41 years.

Figures 1, 2, and 3 are examples. The size is ordinarily a few millimeters in diameter and seldom exceeds 1.5 cm. The perimeter may be sharply defined or gradually fade over a narrow zone into surrounding normal bone. This is especially true of the inferior border.

HISTOLOGIC FEATURES: Tissue curetted from these "lesions" is a red, jelly-like substance. Microscopic examination shows it to consist of normal hematopoietic tissue (Fig. 4). The empty vacuoles are fat cells and the intervening cells are erythrocytes and leukocytes in various stages of maturation. Occasional multinucleated megakaryocytes (precursor cell of platelets) are encountered (arrow).

TREATMENT: None required. This "non-disease" is often incorrectly diagnosed as a cyst, an infection, or tumor.

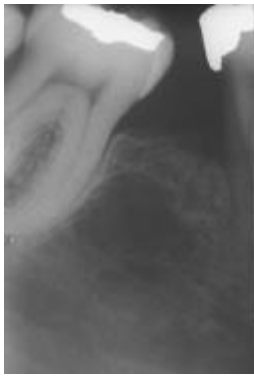

Figure 3

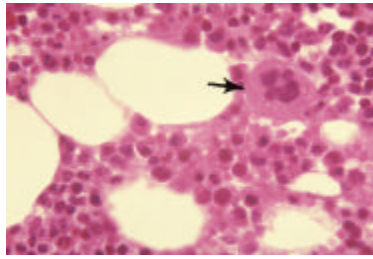


Figure 4

HISTOLOGIC FEATURES: Tissue curetted from these “lesions” is a red, jelly-like substance. Microscopic examination shows it to consist of normal hematopoietic tissue (Fig. 4). The empty vacuoles are fat cells and the intervening cells are erythrocytes and leukocytes in various stages of maturation. Occasional multinucleated megakaryocytes (precursor cell of platelets) are encountered (arrow).

TREATMENT: None required. This “non-disease” is often incorrectly diagnosed as a cyst, an infection, or tumor.

OSTEOSCLEROSIS

In sharp contrast to bone marrow defects, osteosclerosis is an area of dense bone within the jaw without apparent cause. There are no signs or symptoms.

RADIOGRAPHIC FEATURES: The size ranges from a few millimeters to several centimeters. Most are less than 1.0 cm. They appear as a homogeneous radiodense area that has a sharp interface with surrounding bone, although some may fade into surrounding bone. Examples are shown in Figures 5, 6 & 7. Their occurrence in areas of previous tooth extractions suggests that some cases of osteosclerosis may be old foci of condensing osteitis or perhaps the result of deposition of excessive bone during the course of bone repair. While some areas of sclerosis may be a reaction to past episodes of trauma or infection, others cannot be explained on that basis and may be developmental malformation. When they occur in the apical area, they are confused with condensing osteitis.

HISTOLOGIC FEATURES: Osteosclerosis is seldom biopsied because it is recognized radiographically. The sclerotic areas consist of dense but otherwise normal bone.

TREATMENT: No treatment is required. The principle reason for recognizing osteosclerosis is to guard against over-diagnosis. Bone lesions such as ossifying fibroma and even osteosarcoma may appear as radiodense lesions. Unlike true tumors, osteosclerosis does not displace teeth, does not expand bone and causes no symptoms.

Osteosclerosis is ordinarily a solitary lesion. In people with several areas of osteosclerosis, Gardner’s syndrome should be suspected. This autosomal dominant inherited condition consists of multiple areas of bone sclerosis (called osteomas), supernumerary teeth, premalignant intestinal polyps, and skin lesions that may be either fibromas or epidermoid inclusion cysts. The jaw osteomas of a Gardner syndrome patient are seen in Figure 8.

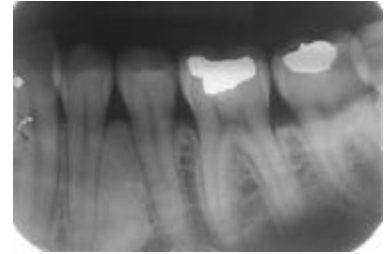


Figure 5

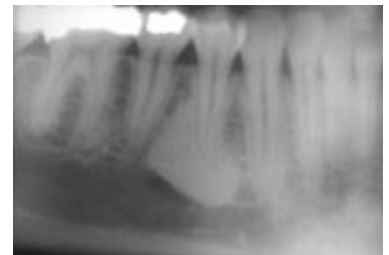

Figure 6

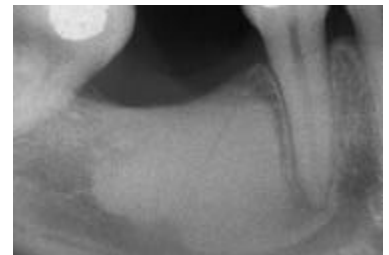


Figure 7

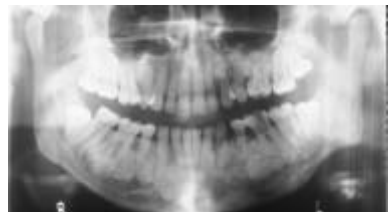

Figure 8

SUBMANDIBULAR SALIVARY GLAND DEFECT

(Also lingual mandibular salivary gland depression, static bone cyst, latent bone cyst, Stafne bone cyst)

The submandibular salivary gland defect is a developmental abnormality that appears as a radiolucent area in the mandible. It may be mistakenly diagnosed as a cyst or a tumor. There are no clinical signs nor symptoms.

RADIOGRAPHIC FEATURES: It occurs as a well-defined radiolucent area, is oval to round, and located below the mandibular canal and above the inferior border of the mandible and just anterior to the angle of the mandible. Figures 9, 10 & 11 are typical. A portion of the perimeter may have a radiodense border.

One survey of almost 5,000 panoramic films uncovered 18 cases of salivary gland defect (0.4%). They are rarely bilateral.

The cause is a developmental defect in which a lobe of the submandibular salivary gland encroaches on the developing mandible. The mandible has a scooped-out surface defect to accommodate the gland. Although the area appears as a hole in the bone, it is really a depression on the lingual surface of the bone.

The sublingual gland will rarely encroach on the mandible to produce a radiographic defect. On even rarer occasions, salivary gland tissue may actually become entrapped in bone and lie dormant for years. In later years, the glandular tissue may become neoplastic and produce the paradoxical situation of a salivary gland cancer arising as a primary cancer within bone.

TREATMENT: No treatment required. Differential diagnosis is usually no problem because of the characteristic appearance and location of the defect.

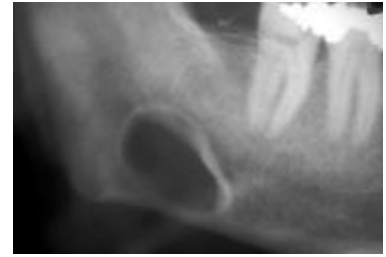


Figure 9

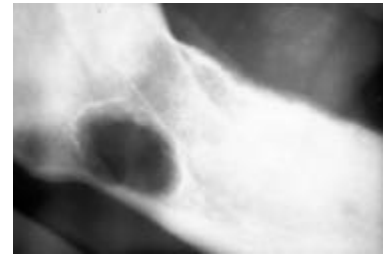

Figure 10

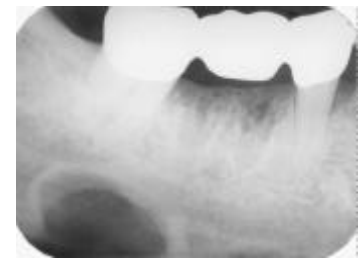

Figure 11

SECTION II

NON-NEOPLASTIC DISEASES OF BONE

OSTEOGENESIS IMPERFECTA

(Also brittle bone disease, Lobstein's disease.)

Osteogenesis imperfecta is an inherited disease of the skeleton and other connective tissues caused by mutations in the genes that code for type I collagen. Autosomal recessive and dominant forms have been described and there are four subtypes. Collagen is the main component of bone matrix, dentin, tendons, ligaments and the sclera. The skeleton bears the brunt of the disease.

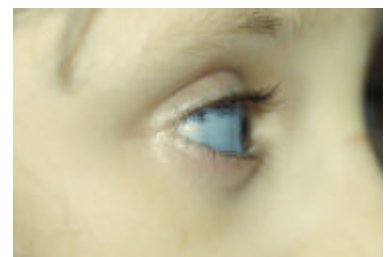


Figure 12

CLINICAL FEATURES: This disease is apparent at birth or becomes evident in the first few days of life. The skeleton is reduced in size, is porous with thin cortices, has small and widely spaced trabeculae, and is extremely susceptible to fracture. The fractures heal but with the same imperfect bone. A severely affected child experiences fractures with the slightest trauma and their skeleton cannot support their own weight. Hypermobility of the joints is another indication of the widespread nature of this disease. The outer layer of the eye, the sclera, is thin and the pigmented cells of the choroid show through. This gives a blue or slate gray color to the eye as seen in Figure 12.

The dental condition known as dentinogenesis imperfecta is often inherited with osteogenesis imperfecta. Figure 13 is an illustration of the teeth of the patient shown in Figure 12.

RADIOGRAPHIC FEATURES: Figure 14 illustrates the radiographic features of the disease; it is the arm of a 4-year-old girl. The cortex is thin, and the deformity caused by multiple fractures is apparent.

HISTOLOGIC FEATURES: For obvious reasons, microscopic material is difficult to obtain. We must rely on what others have reported. The bones show thin cortices and decreased numbers of trabeculae that are abnormally thin. Marrow spaces are correspondingly larger than normal.

TREATMENT: There is no cure for this disease, complications such as fractures are treated as they occur. In severe cases, skeletal growth is greatly retarded and there is extensive deformity. We now live in the age of gene therapy. Ultimately, transplanted stem cells and appropriate cytokines that promote osteoblastic differentiation will be an effective treatment for this disease.

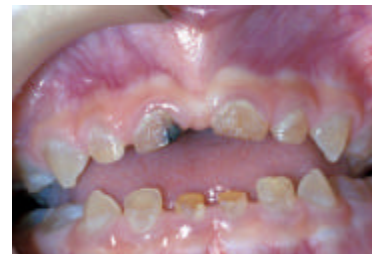

Figure 13

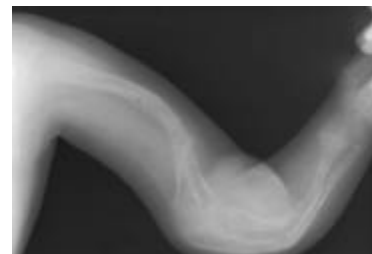


Figure 14

OSTEOPETROSIS

(Also marble bone disease, Albers-Schonberg disease)

Osteopetrosis is an inherited disease of bone in which there is failure of normal osteoclastic resorption. Autosomal dominant and recessive forms exist; the latter is more serious and affected infants may be stillborn or die soon after birth. Fortunately, the disease is rare.

Although osteoclasts fail to resorb bone, osteoblasts exhibit normal function. The imbalance between osteoblastic apposition of bone and osteoclastic resorption leads to increasing bone density throughout the skeleton.

CLINICAL FEATURES: There are several consequences of a dense skeleton. Surprisingly, affected bone fractures more easily, probably because trabeculae are not properly molded and aligned along planes that buttress the bone against stress.

As the bone becomes more dense, the marrow volume is correspondingly reduced. This accounts for the major hematologic complication of myelophthitic pancytopenia. Patients may be severely anemic with erythrocyte levels of less than 1 million mm^3 . Comparable reductions in platelets may lead to a hemorrhagic diathesis. Similarly, reduction of leukocytes leads to increased risk of infection.

RADIOGRAPHIC FEATURES: The radiographic changes are so characteristic that they are virtually pathognomonic. Bones exhibit a homogenous, fine grain density throughout the skeleton. Normal landmarks are obscured. Figure 15 is a lateral skull film of an affected patient. At first glance, it appears to be a poor quality film. Normal suture lines cannot be seen in the cranium and teeth and sinuses are not seen. Figure 16 is a panoramic view of the jaws of an 11-year-old girl with osteopetrosis. The bone is homogeneously and finely opaque and several teeth that should be erupted are trapped within bone. Radiographs of other bone of the skeleton would show the same dense changes.

LABORATORY VALUES: Cellular elements of the blood may be markedly decreased as discussed above. Serum calcium, phosphorus and alkaline phosphatase levels are normal.

HISTOLOGIC FEATURES: Because the disease is rare and the diagnosis usually made by history and x-

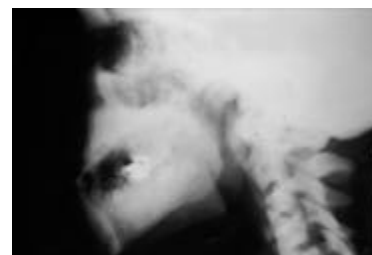

Figure 15

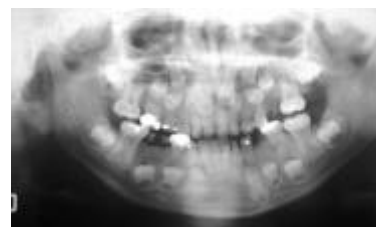

Figure 16

rays, it is uncommon for pathologists to have the opportunity to examine bone from these patients.

Recall that much of the skeleton is first formed in cartilage which mineralizes and is then resorbed (by osteoclasts) and replaced with bone. Throughout life, bone is constantly remodeled by balanced osteoblastic and osteoclastic activity.

In tissue sections of those affected early in life, residual islands of unresorbed mineralized cartilage are found throughout the skeleton, evidence of osteoclastic inactivity. Bone is not remodeled and shaped to body needs and marrow spaces are reduced to near extinction resulting in pancytopenia.

TREATMENT: Formerly there was no treatment for this disease because there was no way to stimulate the patient's own osteoclasts to resorb bone. There has been at least one successful treatment of osteopetrosis by bone marrow transplantation. (New Eng. J. Med., Vol. 302, p. 701, March 27, 1980). In this report, a female child with autosomal recessive malignant osteopetrosis was near death due to severe pancytopenia. A brother who was a close histocompatibility match donated 180 ml of bone marrow that was transplanted to his affected sister. Within days, the girl's blood values improved and she began to excrete increased urinary calcium, evidence her bone was being resorbed. Several months after the transplant, a bone biopsy showed active osteoclastic resorption with many resorption lacunae. The transplanted marrow had provided badly needed osteoclasts.

* For a discussion about recent findings in osteopetrosis and other genetic diseases in humans, go online to: OMIM ([Online Mendelian Inheritance in Man](#)). Click home page.

PAGET DISEASE (Osteitis deformans)

Paget disease is a skeletal disease of unknown cause. Recent evidence indicates this disease is triggered by infection of osteoclasts with the measles virus or respiratory syncytial virus (RSV). It may affect a single bone (monostotic form) or multiple bones (polyostotic form).

In the early years, osteoclastic resorption of normal bone is accelerated. Abnormal bone is removed, new and abnormal bone is formed by heightened osteoblastic activity. In the late phase, osteoclastic resorption wanes and osteoblastic apposition predominates. The disease may "burn-out" leaving enlarged and dense bone comprised of atypical trabeculae of "Paget bone."

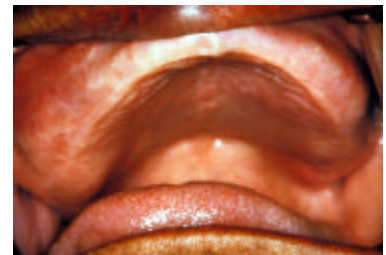


Figure 17

CLINICAL FEATURES: It is uncommon for Paget disease to occur before age 40. Men and women are affected equally. The incidence has been estimated to be as high as 3% of the adult population. It is a chronic disease which in its worst form causes severe pain. Weight bearing bones break easily or may slowly bend under pressure to produce crippling, bowing deformities and compression of spinal nerves. If the base of the skull is affected, narrowing of cranial foramina may cause deafness and blindness.

Although any bone may be affected, the disease favors bones in the midline. Sacrum, spine, skull, pelvis and the large tubular bones of arms and especially the legs are most commonly affected. Facial bones, jaws, ribs and those bones distal to the elbow and knee are far less often involved. The frequency of jaw involvement is uncertain, but one study cites an incidence of 17%. The maxilla is more often involved than the mandible.

Involved bones become progressively larger; flat bones become thicker and round bones increase in circumference. Hats and dentures may no longer fit and in medical lore, these signs have become classic. Teeth may drift apart as the jaws enlarge. Figure 17 is of a 50-year-old female with involvement of the right maxilla. Notice the bulky expansion of the patient's right maxilla compared to her left. (Please consult your text for other pictures.)

Patients with Paget disease have an increased risk of developing sarcoma of bone, chiefly osteogenic sarcoma. The incidence of sarcoma has been reported to be as high as 15% but a study with long follow-up of almost 4,000 patient revealed a rate of 0.95% sarcomatous change.

RADIOGRAPHIC FEATURES: The radiographic appearance varies with the stage of the disease.

Early Stage — Osteolysis dominates and the lesion is radiolucent.

Middle Stage — Apposition of “Paget bone” creates islands of density within the radiolucent lesions. These islands lack the normal trabecular pattern and are homogeneously dense. Because they resemble tufts of cotton, they are called “cotton wool” densities. Figure 18 illustrates this in the skull.

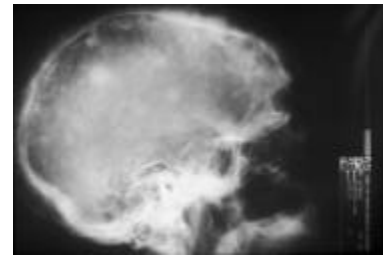


Figure 18

Late Stage — Osteoblastic apposition of Paget bone continues as osteoclastic activity subsides. The bone becomes homogeneously dense. When jaws are involved, the teeth often show hypercementosis.

LABORATORY VALUES: Serum calcium and phosphorous levels are normal but the serum alkaline phosphatase level is increased to levels not seen in other bone diseases.

HISTOLOGIC FEATURES: Microscopic features vary with the stage of the disease. The disease is a struggle between osteoclasts and osteoblasts. In the early stages, osteoclastic resorption outpaces osteoblastic activity. Figure 19 illustrates numerous osteoclasts in resorption lacunae (Howship's lacunae). As resorption and apposition wax and wane, the trabeculae become abnormally shaped. They are small, angulated and often terminate in sharp points or scimitar shape. Episodes of resorption and apposition result in numerous “reversal” lines which make each trabeculae appear to be composed of several smaller pieces fitted together. This is known as the “Chinese character,” “jigsaw puzzle” and “mosaic” pattern and is highly suggestive of Paget disease. This is best seen in sections heavily stained with hematoxylin as shown in Figure 20. The marrow of Paget bone shows fibrous replacement, lymphocytic infiltration and vascular dilation.

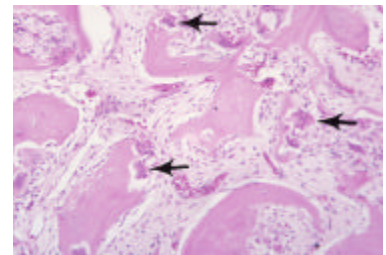


Figure 19

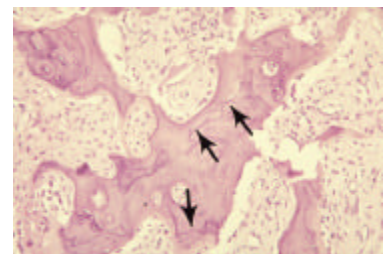


Figure 20

- SUMMARY:**
1. Osteoclastic resorption and osteoblastic apposition, sometimes in the same field.
 2. “Mosaic” trabeculae.
 3. Fibrous connective tissue replacement of the normal fatty marrow.
 4. Vascular dilation.
 5. Lymphocytic infiltration suggesting an inflammatory basis for the disease.

TREATMENT: Mild cases are asymptomatic and require no treatment. Pain may be controlled with aspirin or indomethacin. Steroids have been reported to suppress the disease but require large doses with the risk of Cushingoid syndrome. Large doses of sodium fluoride (up to 120 mg/day) may ameliorate symptoms, and subcutaneous injections of calcitonin reduce the rate of osteoclastic resorption. More recently disodium etidronate has been found to reduce bone resorption and symptoms.

FIBROUS DYSPLASIA

Of all bone diseases, fibrous dysplasia is one of the most mysterious. The discovery of a gain in function mutation in the gene encoding the signal transducing G protein has provided new insight to this old disease. The basic defect appears to be a benign proliferation of fibroblasts arising within bone marrow. Normal trabeculae of bone undergo osteoclastic resorption to make room for the expanding cellular mass. Some of the growing fibroblasts undergo metaplasia to become osteoblasts. New bone is formed within the cellular mass. The new bone is abnormal however, and consists of small and highly irregularly-shaped trabeculae of embryonic or “woven” bone. The net result is a tumor-like enlargement of the affected bone that is weakened and vulnerable to pathologic fracture.

CLINICAL FEATURES: This disease appears more often in youth and there is no sex preference. A single bone may be involved (monostotic form) or multiple bone involvement may occur (polyostotic form). In the polyostotic form, other organ system abnormalities may be seen. Multiple bone lesions of fibrous dysplasia accompanied by large patches of melanotic skin pigmentation had been referred to as the “Jaffe” variant. Bone lesions with skin pigmentation and endocrinopathy are referred to as “Albright’s syndrome.” The main endocrine disturbance in Albright’s syndrome consists of precocious puberty in females and hyperthyroidism in males.

Affected bone(s) become enlarged with cortical thinning. Although ordinarily painless, this growth may encroach on other structures (maxillary sinus) or cause pathologic fractures.

Figure 21 is a 19-year-old female with a history of slow, painless, enlargement of the mandible that proved to be fibrous dysplasia.




Figure 21

RADIOGRAPHIC FEATURES: The radiographic features are so variable that one wonders if all reported cases are examples of the same disease. Purely radiolucent forms have been described, but the most common appearance is that of a finely trabeculated radiodensity, the so called “ground glass” appearance.

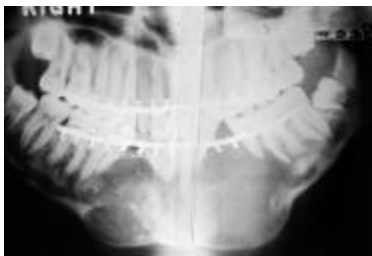

Figure 22

Most authors believe that fibrous dysplasia lacks a sharply demarcated border. The lesions blend into surrounding normal bone so that on the radiograph, the clinician may not see a definite junction between normal and abnormal. Figure 22 illustrates fibrous dysplasia of the mandible and Figure 23 shows “ground glass” density of the maxilla encroaching on the sinus.

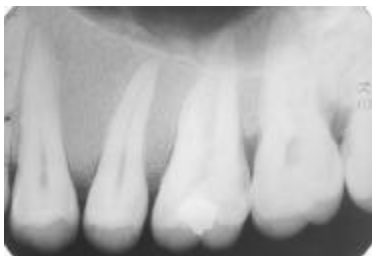

Figure 23

LABORATORY VALUE: Fibrous dysplasia causes no significant abnormalities in blood calcium, phosphorus or serum alkaline phosphatase.

HISTOLOGIC FEATURES: Figure 24 shows fibrous dysplasia. The marrow is replaced by cellular fibrous connective tissue. Bone trabeculae are small and irregularly shaped.

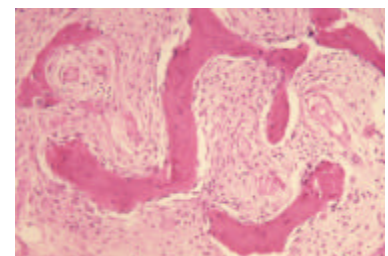


Figure 24

TREATMENT: Surgery is the only treatment. Small lesions may be adequately treated by simple curettage, but larger lesions require

resection of the involved part. In the jaws, cosmetic reductions are sometimes attempted by simply shaving the surface of the bone to the original contour.

Radiation therapy is contraindicated. Several patients who have been irradiated have developed osteogenic sarcoma. It appears that in some instances, radiation may convert a benign lesion into a malignant one.

DIFFERENTIAL DIAGNOSIS: Some features of fibrous dysplasia may resemble Paget disease but there are important differences.

| | Fibrous Dysplasia | Paget Disease |
|-----------|---|--|
| Age | Youth | Over 40 |
| Serum | No abnormality | Alkaline phosphatase increased |
| X-ray | Homogenous density "ground glass" pattern. | Lucent to dense depending on stage. "Cotton wool" pattern is classic. |
| Histology | Abnormal trabeculae of immature (woven) bone in a fibrous marrow. | Extensive osteoclastic and osteoblastic activity surrounding "mosaic" trabeculae with vascular dilation and lymphocytic infiltration of marrow |

CHERUBISM

This rare, inherited disease is characterized by marked fullness of the face. The cause has been traced to mutations in the SH3BP2 gene on chromosome #4 (Nature Genetics 28(2) June 2000). Involvement of the maxilla causes expansion with upward displacement of the eyes producing the so-called "heavenly gaze." The name "cherubism" comes from the cherubic facial appearance depicted in angelic children commonly seen in Renaissance art. The disease has little in common with fibrous dysplasia of the jaws. The name familial fibrous dysplasia of the jaws is a misnomer.

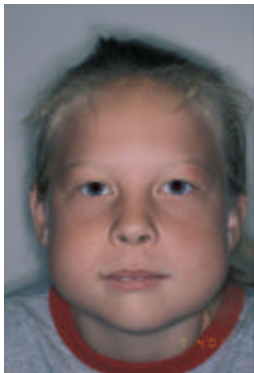

Figure 25

CLINICAL FEATURES: The jaws show firm, bilateral, painless swellings as shown in Figures 25 and 26. The disease occurs mainly in the mandible, but may also involve the maxilla. The swelling usually begins in the posterior regions of the jaws, classically the mandibular rami. No other bone in the body is affected with rare exception. Occasionally, enlarged submandibular lymph nodes are present without evidence of infection.

Cherubism has an early onset, usually by age five. It progresses steadily during the childhood years. It is usually inherited as an autosomal dominant trait but sporadic cases have been reported. Primary and secondary teeth of the affected child may be absent, irregularly shaped, impacted, displaced and/or may have an abnormal eruption sequence.

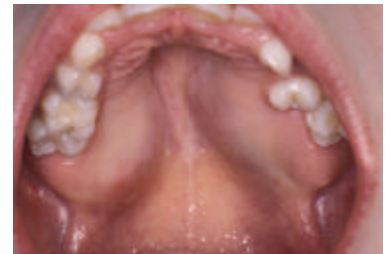

Figure 26

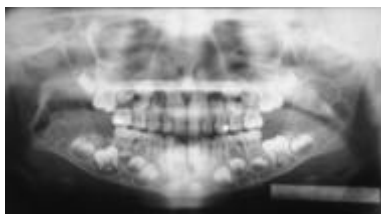


Figure 27

RADIOGRAPHIC FEATURES: Cherubism appears as radiolucent and multilocular lesions. Typically, lesions begin in the mandibular rami and advance anteriorly. A patient with beginning lesions in both rami is illustrated in Figure 27. A more advanced case is seen in Figure 28. The radiographic features are virtually pathognomonic. No other disease of the jaws is bilaterally symmetrical and begins at such an early age.

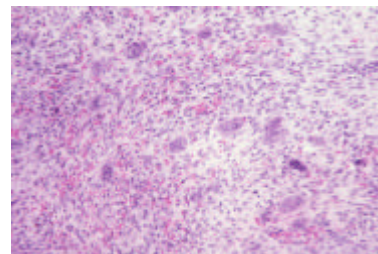


Figure 29

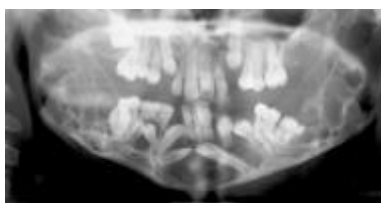


Figure 28

HISTOLOGIC FEATURES: Multinucleated giant cells distributed among spindle-shaped fibroblasts is the characteristic finding. These are demonstrated in Figures 29 and 30.

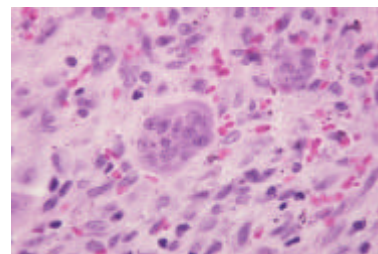


Figure 30

TREATMENT: The disease may be self-limiting. The lesions may stop growing and regress during the

teens. Surgical curettage may achieve cosmetic improvement in those patients with unsightly jaw enlargement. Radiation therapy is contraindicated since it may interface with facial growth and may also induce sarcomatous change.

FLORID OSSEOUS DYSPLASIA (FOD)

(Also: Chronic Diffuse Sclerosing Osteomyelitis, Sclerotic Cemental Masses of the Jaws; Multiple Enostosis, Gigantiform Cementomas, and others)

The excess of names for this disease reflects the uncertainty of its origin. Although may regard this as a disease of bone, others think it is of cementum.

We are all taught that cementum is a distinct tissue different from bone. However, in chemical composition and structural organization, they are similar. Additionally, there are two diseases of bone that have a profound effect on cementum: 1) hypophosphatasia produces a severe rickets-like defect of the entire skeleton and cementum is deficient or absent, and 2) Paget disease of the jaws often causes hypercementosis of the teeth. If bone and cementum are distinctly different, why do these two bone diseases have an effect on cementum? We believe cementum may be a variant of bone. If this is true, diseases of cementum are, in reality, diseases of bone.

CLINICAL FEATURES: This disease exhibits a strong predilection for middle-aged, black females. In one reported series of 34 patients, 33 were female and 32 were black. The age ranged from 26 to 59 with a mean of 42 years. Duration was from 6 months to 29 years. Twenty-three patients were without symptoms, the others complained of intermittent, dull pain. Approximately half of the 34 patients had expansion of the involved bone, but expansion is rarely sufficient to produce facial swelling. Fluid containing bone cavities (cysts) were found in 14 patients.

Approximately 50% of patients have involvement of both maxilla and mandible, others have only a single jaw involved. Disease in only one quadrant of one jaw is uncommon.

RADIOGRAPHIC FEATURES: The typical case of osseous dysplasia shows radiodense masses with surrounding halos of radiolucency. This is easily seen in Figure 31 in which lesions are seen in both quadrants of the mandible.

In some cases, the lesions seem to originate around the roots of teeth (Figure 32). As the dense material grows, it may attach to the roots of teeth. These observations are taken as evidence the material is cementum. Figure 33 shows large, sclerotic masses in both quadrants of the mandible in a 75-year-old, black female. Some patients have solitary lesions of osseous dysplasia. These have been described as focal cemento-osseous dysplasia (FCOD). It is likely that ordinary cementomas, FCOD and FOD are different degrees of severity for the same disease. FCOD is illustrated in Figure 34.

LABORATORY VALUES: There are NO blood abnormalities.

HISTOLOGIC FEATURES: Figure 35 illustrates the microscopic features. In the upper left, trabeculae of newly formed matrix resemble bone whereas in the lower right, round and acellular deposits resemble cementum. We regard all this lesional material as bone.

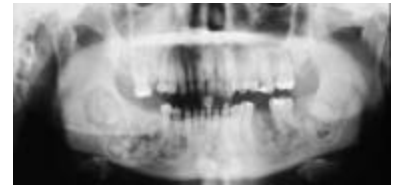


Figure 31

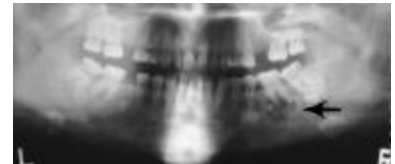


Figure 32



Figure 33

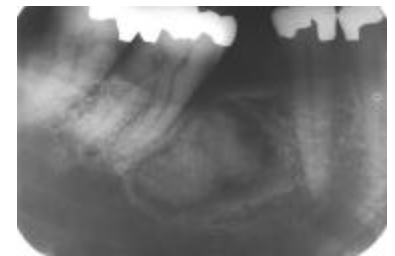

Figure 34

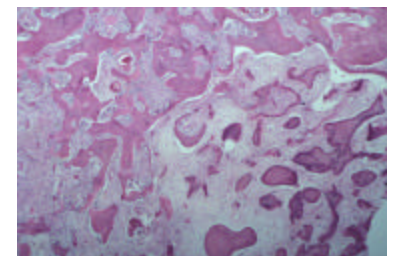


Figure 35

The intervening stroma is made of cellular and benign fibrous connective tissue. In Figure 36, cellular but benign fibrous connective tissue fills the marrow. Osteoblasts line the trabeculae and vascular dilation is evident. The histology has several features in common with fibrous dysplasia and Paget disease.

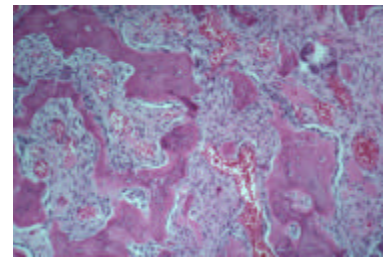


Figure 36

TREATMENT: Uncomplicated osseous dysplasia requires no treatment. The natural course of this disease is slow growth for a number of years followed by surgical treatment which is often followed by osteomyelitis.

Therefore, teeth should not be extracted without good reason. Traumatic ulceration of overlying mucosa also predisposes to infection. Denture fit should be carefully monitored to avoid this.

In those cases with superimposed infection, sequestrectomy with primary closure and antibiotics are the accepted treatment.

SECTION III Bone Tumors

CENTRAL GIANT CELL REPARATIVE GRANULOMA (GIANT CELL TUMOR)

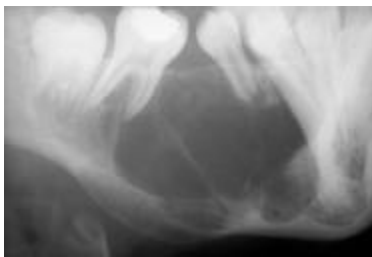


Figure 37

CGCRG is a controversial lesion arising centrally within bone. The name suggests it is a reparative lesion, but the absence of a history of trauma in most patients casts doubt on this theory. This lesion is seldom found outside the jaws although a histologically similar (if not identical) tumor occurs in all other bones of the skeleton. This latter is called “true giant cell tumor” and is regarded as a true neoplasm in contrast to the CGCRG which is regarded by many as an exuberant hyperplasia.

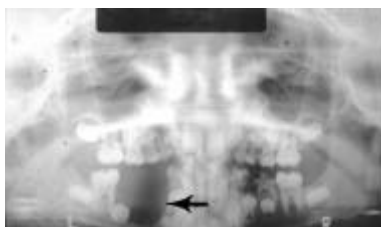


Figure 38

CLINICAL FEATURES: The “rule of two-thirds” will remind you that two-thirds of patients are female, two-thirds are under age 30, and two-thirds occur in the mandible. Pain, expansion or a feeling of fullness may call attention to the tumor. The middle and anterior segments of the jaws are most frequently involved, seldom are these lesions found posterior to the first molar area.

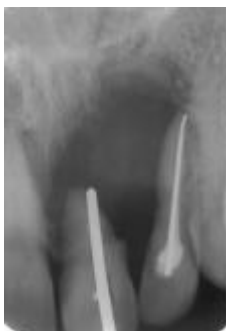

Figure 39

RADIOGRAPHIC FEATURES: The lesion is purely radiolucent. It may be unilocular or multilocular with classic “soap bubble” appearance. Adjacent teeth may be resorbed or moved bodily. Figures 37, 38 and 39 are examples of CGCRG. In Figure 39, the clinician did endodontic filling because the lesion was mistakenly diagnosed as periapical cyst. Although large tumors cause jaw expansion, it is uncommon for the tumor to penetrate the cortex. Multilocular lesions may be confused radiographically with ameloblastoma, myxoma, aneurysmal bone cyst and hemangioma.

HISTOLOGIC FEATURES: The tumor consists of a solid, cellular proliferation of oval to spindle fibroblasts that lack pleomorphism and have few mitoses. Scattered throughout these stromal cells are numerous multinucleated giant cells that give this tumor its name. Figures 40 and 41 are medium and high power views of this tumor. Notice the giant cells (osteoclasts) in a stroma or mononuclear stromal cells.

TREATMENT: Curettage is usually curative but there is a recurrence rate of approximately 20%. Some success has been achieved by the intralesional injection of steroid. Additionally, subcutaneous injection of

calcitonin may be an alternative to surgery. A single case of success with interferon alpha 2a has been reported.

DIFFERENTIAL DIAGNOSIS: Microscopically, CGCRG is similar to cherubism, aneurysmal bone cyst and “brown” tumors of hyperparathyroidism. The bilateral nature and genetic aspects of cherubism help in differentiating it from giant cell granulomas. Aneurysmal bone cyst (ABC) ordinarily has blood-filled, cavernous spaces helpful in the diagnosis. Patients with hyperparathyroidism have elevated serum calcium which is not seen in patients with giant cell granuloma.

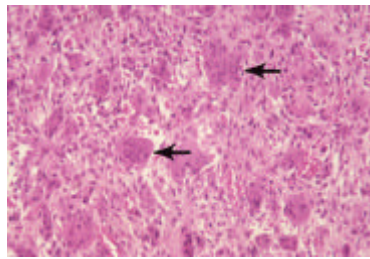


Figure 40

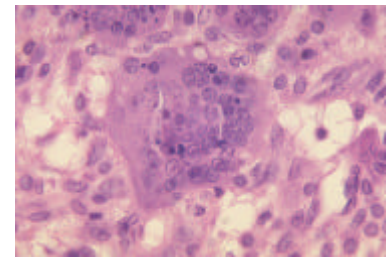


Figure 41

OSSIFYING FIBROMA/CEMENTIFYING FIBROMA

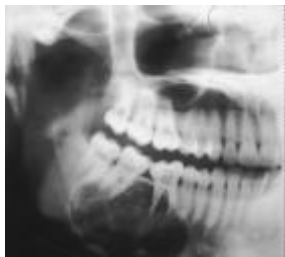

Figure 42

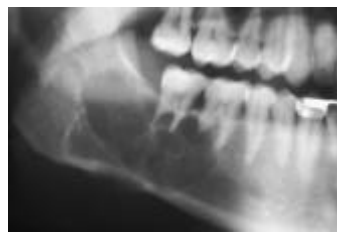

Figure 43

These two tumors are generally regarded as variants of the same process and will be discussed as a single entity. This is a benign tumor arising centrally within bone. It is composed of fibroblasts sometimes exhibiting a compact, whirled appearance with variable amounts of collagen between tumor cells. Small droplets of calcified material may be produced. This bears a resemblance to cementum and such a lesion is

designated “cementifying” fibroma. They are identical in radiographic appearance and clinical behavior.

CLINICAL FEATURES: Although this tumor is not rare, neither is it common. No single author has published a large series. Data on 54 cases shows a mean age of 34 with a 2/1 female preference. It occurs in both jaws, but the molar-premolar region of the mandible is the most common site. As in many other jaw tumors, the most common symptom is slow and painless expansion of the affected jaw.

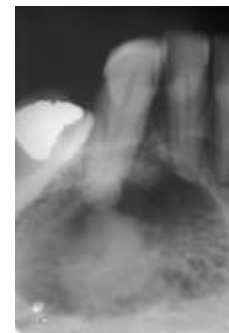


Figure 44

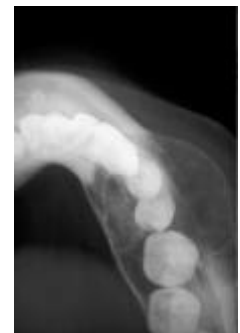

Figure 45

RADIOGRAPHIC FEATURES: The appearance is variable and depends on the amount of bone (cementum) produced. Those tumors with little calcified material are radiolucent. Those with much calcified matrix are radiodense. Intermediate degrees of radiolucency-radiodensity may be seen.

The border of the tumor is usually sharply circumscribed which helps in distinguishing this tumor from fibrous dysplasia which it may resemble microscopically. Unilocular and multilocular forms exist. Teeth in the area may be displaced and/or resorbed. Figures 42, 43, 44 and 45 illustrate ossifying/cementifying fibroma.

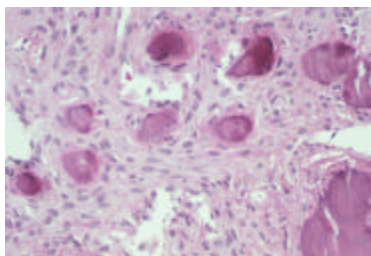


Figure 46

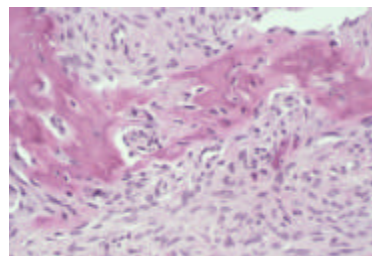


Figure 47

HISTOLOGIC FEATURES: The tumor consists of a compact mass of fibroblasts that exhibit no nuclear pleomorphism. Tumor cells are oval to spindle shape and secrete variable amounts of collagen. In the variant known as cementifying fibroma, acellular droplets of calcified matrix are produced (Figure 46). In the “ossifying” fibroma, tra-

beculae of bone are produced (Figure 47). This tumor does not have a capsule but the interface between

tumor and surrounding bone is sharp.

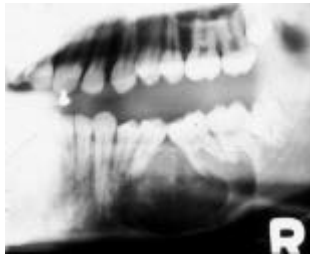

Figure 48

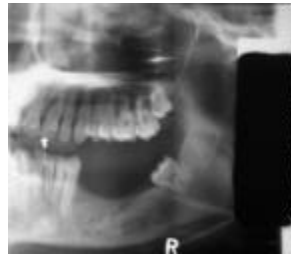

Figure 41

TREATMENT: The treatment is curettage, recurrence is infrequent. Figure 48 is an ossifying fibroma in a 16-year-old girl. Figure 49 is the same patient 10 months following curettage. Several teeth were sacrificed but notice how bone has filled in the surgical site.

EWING SARCOMA

Ewing sarcoma is a malignant tumor arising in bone. The cell of origin is unknown, but there is evidence that the tumor is derived from primitive neuroectodermal cells. A variety of chromosome abnormalities have been identified in tumor cells, the most common a 11/22 reciprocal translocation. Microscopically, the tumor consists of compact masses of small, round cells with uniform nuclei and scant cytoplasm. To the surgical pathologist, Ewing tumor is difficult to distinguish from other tumors composed of small, round cells such as lymphocytic lymphoma, Burkitt's lymphoma, neuroblastoma, and embryonal rhabdomyosarcoma.

CLINICAL FEATURES: This tumor is seen chiefly in youth. Most patients are under age 20. Pain and swelling are the most common complaint. The patient may have fever, leukocytosis and increased erythrocyte sedimentation rate leading to an incorrect diagnosis of an infection rather than a tumor. No bone is immune to Ewing tumor but 60% occur in the pelvis and legs. Unlike many bone tumors which favor the ends (epiphysis and metaphysis) of tubular bones, Ewing tumor is often found in the shaft (diaphysis). Ewing tumor in the jaws is a rarity.

RADIOGRAPHIC FEATURES: The tumor produces no mineralized matrix and therefore appears as a pure radiolucency. The border may be indistinct in contrast with benign tumors which often are sharply demarcated. As the tumor breaks through cortex, the periosteum may lay down successive layers of reactive bone to produce the classic "onion skin" appearance. Radiating spicules from the tumor surface may also mimic the sunburst appearance of osteosarcoma. Figures 50 and 51 are radiographs of a large Ewing tumor in the midline of the anterior maxilla. The patient presented with swelling and epistaxis (nose-bleed).

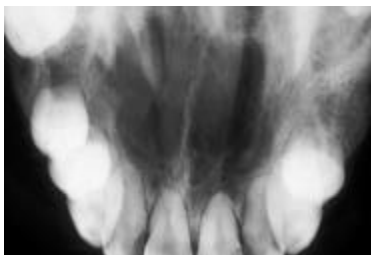


Figure 50

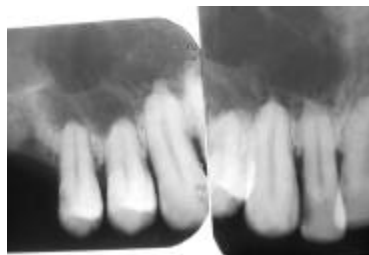


Figure 51

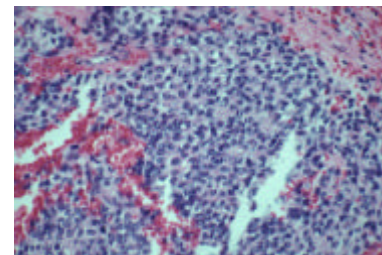


Figure 52

HISTOLOGIC FEATURES: The tumor is composed of sheets of compact, small, round tumor cells with uniform nuclear size and scant cytoplasm. Trabeculae of fibrous stroma may course through the tumor dividing sheets of tumor cells into small aggregates. Figure 52 is a medium-power view of an Ewing tumor. Approximately 80% of Ewing tumors will have tumor cells whose cytoplasm is rich in glycogen. This can be demonstrated with the PAS (periodic acid-Schiff) stain. This is helpful in distinguishing this tumor from other small cell tumors, most of which lack glycogen.

TREATMENT: Ablative surgery, high-dose irradiation, and chemotherapy are combined in the treatment of

this dreadful tumor. Sixty-six patients with Ewing tumor treated at the National Cancer Institute with combined radiation therapy and intensive chemotherapy (adriamycin, cyclophosphamide and vincristine) had a 52% five-year survival in those who had no detectable metastases at the time of diagnosis. Not many years ago, virtually all patients with this tumor died.

OSTEOGENIC SARCOMA (Osteosarcoma)

Osteogenic sarcoma is a tumor of malignant osteoblasts. Osteosarcoma can be induced in laboratory animals with the radioactive elements strontium and radium, Harvey mouse sarcoma virus, methycholanthrene and beryllium. Furthermore, patients with benign bone disease such as fibrous dysplasia who are inappropriately treated with radiation may experience conversion of their benign disease into osteogenic sarcoma.

CLINICAL FEATURES: Osteosarcoma occurs in all bones of the skeleton; the distal metaphysis of the femur is the most common site. This is a tumor of youth and peaks in the second and third decades. A patient over age 40 with osteosarcoma should be suspected of having underlying Paget disease.

The chief signs and symptoms are swelling and pain at the affected site. Growth of the tumor is rapid and metastasis generally occurs within two years of the appearance of the primary tumor. Although hematogenous metastasis is the primary pathway, lymphatic spread does occur. Lung metastases result from hematogenous spread. Regional lymph node metastases are the result of lymphatic dissemination.

It is estimated that 6% of osteosarcomas arise within the jaws. The tumor affects both sexes equally and the mean age of patients with jaw tumors is approximately 31 years, 10 years older than for tumors that arise in other bones. The mandible is more often involved than the maxilla. In one series of 56 osteogenic sarcomas of the jaws, 38 were mandibular (2 to 1 ratio). The most common symptoms of jaw tumors in descending order were swelling (Figure 53), pain, loose teeth, paresthesia, toothache, bleeding, nasal obstruction, separated teeth and headache.

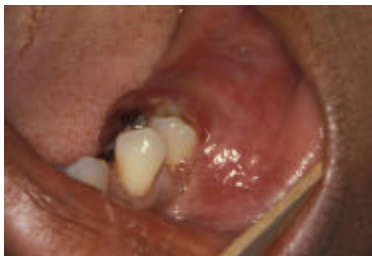

Figure 53

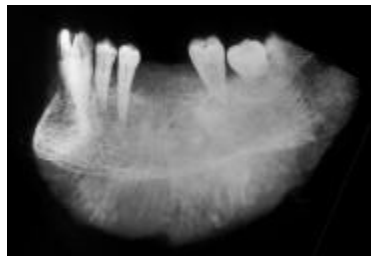


Figure 54

RADIOGRAPHIC FEATURES: As with many bone tumors, both benign and malignant, the radiographic appearance is variable and depends on the amount of tumor bone synthesized by the malignant osteoblasts. In those tumors with little tumor bone, the radiographic appearance will be radiolucent; whereas those tumors with much

tumor bone will be radiodense. Mixed lucent-dense lesions indicate an intermediate degree of tumor bone formation. There are three features of osteosarcoma that are classics: 1) small streaks of bone radiate outward from approximately 25% of these tumors. This produces a sunray (sunburst) pattern. This is shown in a resected osteosarcoma of the mandible in Figure 54; 2) in the jaws, this tumor may grow within the periodontal membrane space causing resorption of the adjacent bone resulting in uniform widening of the space (Figure 55). Widening of the periodontal membrane space may also be seen in other conditions such as chondrosarcoma and scleroderma so it is not pathognomonic; and 3) in the long bones affected with osteosarcoma, the periosteum is elevated over the expanding tumor mass in a tent-like fashion. At the point on the bone where the periosteum begins to lift (edge of the tent), an acute angle between the bone surface and the periosteum is created. This is called Codman's triangle and is highly suspicious for osteosarcoma (not illustrated).

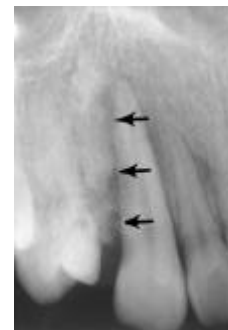


Figure 55

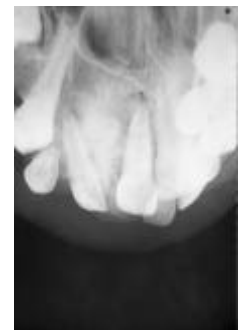

Figure 56

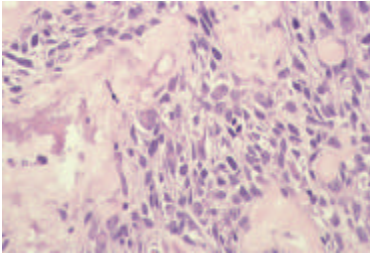


Figure 57

Figure 56 is a film of a radiodense “osteoblastic” osteosarcoma in the anterior maxilla of an 11-year-old girl. With a little imagination, you can see a slight “sunburst” appearance on the superior aspect.

LABORATORY VALUES: No significant abnormalities.

HISTOLOGIC FEATURES: The tumor cells show nuclear abnormalities, such as atypical mitoses, enlarged nuclei, hyperchromasia and great variation in nuclear size and shape (pleomorphism). Figure 57 is such a tumor, bone formation is seen at 9 o’clock.

Three histologic varieties of osteosarcoma are identified; formation of tumor osteoid (bone) is the common denominator. Some tumors synthesize large amount of osteoid (osteoblastic), others secrete considerable malignant cartilage matrix (chondroblastic), and others secrete little matrix material (fibroblastic).

TREATMENT AND PROGNOSIS: Treatment is ablative surgery and chemotherapy. This tumor arises in the medullary portion of bone, infiltrates adjacent tissues and readily metastasizes. This accounts for the dismal survival rate of around 20%. The role of radiation is controversial. Some advise against it while others use it in conjunction with surgery.

Osteogenic sarcoma arising in Paget disease is aggressive, the 5-year survival rate is approximately 8%. Occasionally, sarcomas arise in the outer cortex of bone (parosteal osteosarcoma) or in the periosteum (periosteal osteosarcoma). These variants are rare, usually show a high degree of differentiation and carry a more favorable prognosis.

In the jaws, mandibular symphysis tumors carry the best prognosis and tumors involving the maxillary antrum the worst. This is not due to intrinsic differences between tumors but most likely is related to the greater ease of surgical resection of the mandibular tumors.

MULTIPLE MYELOMA

Multiple myeloma is a malignant neoplasm of plasma cells. Tumor cells secrete large quantities of immunoglobulin that are detected in the serum by electrophoresis and are referred to as the M (myeloma) component. Any of the five classes of antibodies may be produced but IgG is the most common. Light chains may be produced in excess of heavy chains and are excreted in the urine where they are referred to as Bence Jones proteins. Myeloma has several variants, all of which secrete excess immunoglobulins.

CLINICAL FEATURES: Bone pain caused by multiple plasma cell tumors within bone marrow is often the earliest symptom. Normal hematopoietic tissue is replaced by expanding plasma cell tumors leading to normocytic, normochromic anemia. Hypercalcemia develops as bone is resorbed. Approximately 10% of myeloma patients develop amyloidosis caused by the precipitation of immunoglobulins within organs and tissues. Myelophthitic leukopenia and the inability to elaborate normal antibodies impairs humoral immunity and increases susceptibility to bacterial infections. Kidney failure is a late sequelae of myeloma. Renal tubules become clogged with gelatinous masses, largely of immunoglobulin light chain origin. The kidney also suffers infiltration of abnormal plasma cells. Hypercalcemia may result in metastatic calcification of renal interstitial tissue. Amyloid deposition in the renal glomeruli causes glomerulosclerosis leading to the nephritic syndrome. Pathologic fracture of involved bones is a feature of late stage disease. Although myeloma affects many organs and tissue, the plasma cell tumors in bone marrow are the dominant feature. They occur in any and all bones but favor bones in or near the midline (skull, vertebrae, pelvis, ribs). Tumor cells secrete IL-6, an osteoclast activating cytokine, at least partially accounting for wide-spread bone destruction.

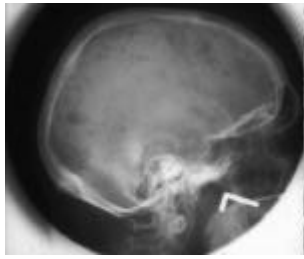


Figure 58

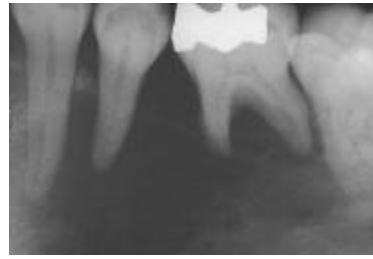

Figure 59

RADIOGRAPHIC FEATURES: Multiple “punched-out” 1-4 cm radiolucent lesions in bone are the characteristic feature (Figure 58). A more diffuse lesion is seen in the jaw on Figure 59.

HISTOLOGIC FEATURES: Diagnosis rests on the microscopic identification of plasma cell tumors within bone. The tumor cells

may exhibit a high degree of differentiation and be remarkably normal appearing or they may be so poorly differentiated that they bear little resemblance to plasma cells. The tumor cells exhibit light chain restriction, they all secrete kappa or lambda light chains but not both. (Recall that plasma cells are differentiated B lymphocytes). Figure 60 is a high power view. Cells are easily identified as plasma cells because of the abundant cytoplasm with eccentric nuclei. In some cells, nuclear chromatin appears in small clumps which resemble numbers on a clock (so-called clock-face appearance). About 8% of myeloma patients develop amyloidosis. A myeloma patient with amyloidosis of the tongue is seen in Figure 61, histology in Figure 62.

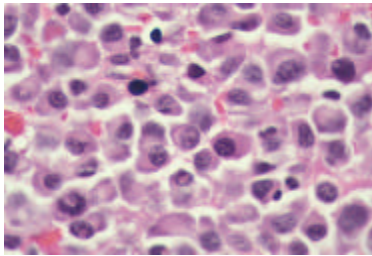


Figure 60

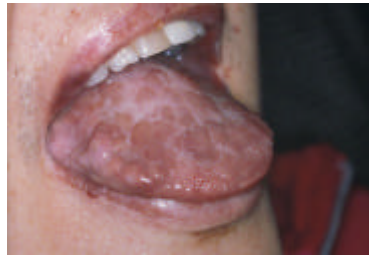

Figure 61

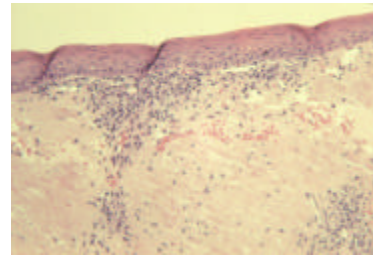


Figure 62

TREATMENT: Remission may be achieved with systemic chemotherapy using prednisone, cyclophosphamide and melphalan. The median survival time with multiple myeloma is approximately three years.

VARIANTS OF MYELOMA

- A. **Solitary Myeloma** — single plasma cell tumor in the skeleton with minimal M-component in serum. Most patient progress into multiple myeloma.
- B. **Soft Tissue Plasmacytoma** — single plasma cell tumor in soft tissue, usually in nasopharynx or oropharynx, minimal M-component (immunoglobulin) in serum. Low risk of progression into multiple myeloma.
- C. **Plasma Cell Leukemia** — A rare variant of MM in which the malignant plasma cells are released from marrow and flood the circulation.

DISEASES CLOSELY RELATED TO MYELOMA

- A. **Waldenstrom macroglobulinemia** — a malignancy of B lymphocytes in which the degree of cellular differentiation lies halfway between lymphocyte and plasma cell. These tumors secrete mostly IgM and many of the clinical symptoms of the disease are caused by the resultant hyperviscosity of the blood (retinal and cutaneous hemorrhage, confusion and paresis). Tumor masses are not confined to bone marrow but may also occur in lymph nodes and spleen.
- B. **Benign monoclonal gammopathy** — a small number of adults will be found to have a slight increase in circulating monoclonal (single type) antibody but no evidence of plasma cell tumors. These patients are prone to amyloidosis but few, if any, progress to myeloma.
- C. **Heavy chain disease** (Franklin’s disease) — a plasma cell dyscrasia resembling Waldenstrom except only heavy chains are produced.

LANGERHANS' CELL GRANULOMATOSIS (Langerhans' cell histiocytosis, LCH)

Clonal expansion of Langerhans' cells creates a spectrum of diseases whose unknown cause and unpredictable behavior have thwarted attempts at classification. The recognition that LCH is a monoclonal proliferation and when disseminated, is aggressive and potentially fatal suggests it is neoplastic. The indolent behavior of localized lesions and instances of spontaneous regression suggest otherwise. Despite monoclonality, LCH may eventually prove to be a condition whose underpinning is the loss of regulatory control of an immune response.

Although generally thought of as a childhood disease, LCH has been encountered from infancy through the 9th decade of life. Few organs are immune but bone, lung, skin, lymph nodes and the hypothalamus/pituitary axis bear the brunt of the disease. The clinical presentation is wide ranging. The most common is unifocal or multifocal osseous disease. Approximately 30% have disseminated multisystem disease. The time honored eponyms of Letterer-Siwe disease (disseminated disease), Hand-Schuller-Christian disease (intermediate severity) and eosinophilic granuloma (localized disease) is archaic.

In the mouth, LCH is often announced by unexplained pain in the maxilla or mandible. The overlying mucosa may be swollen or ulcerated. The mandible is more often involved than is the maxilla. It is found chiefly in the young, most patients are under the age of 30.

The radiographic features are not diagnostic; biopsy is required for diagnosis. Lesions are invariably radiolucent, the border may be well-defined or indistinct. Lesions of LCH occur chiefly in the tooth bearing areas of the jaws (Figures 63, 64 and 65). Painful and destructive lesions around the teeth may be confused with infections of dental origin. The teeth are innocent bystanders and when incorporated in the lesions of LCH, they may be bodily displaced or roots may undergo resorption.

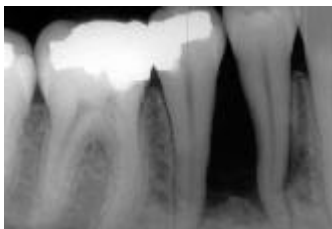

Figure 63

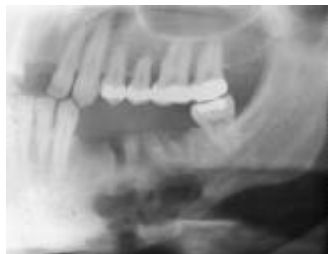

Figure 64

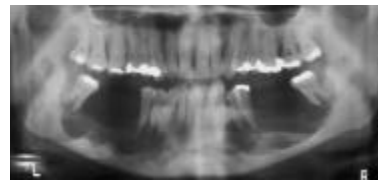


Figure 65

Seldom do the microscopic features present a diagnostic problem. Sheets of mononuclear macrophages (Langerhans cells) efface the normal architecture (Figure 66). They are often accompanied by varying numbers of eosinophils and occasional multinucleated giant cells. Langerhans' cells are identified by a positive reaction to the anti-S100 immunoperoxidase stain. It is ordinarily not necessary to demonstrate other identifying features such as surface CD1a and cytoplasmic Birbeck granules.

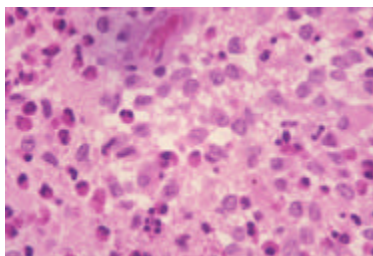


Figure 66

Chemotherapy is the mainstay of disseminated disease. Prednisone and vinblastine are one of the several regimens. For unifocal bone disease, the form most commonly encountered in the jaws, surgical curettage alone or in combination with external beam, low-dose radiotherapy provides a cure rate of approximately 90%. The optimum dose of radiotherapy has not been established but ordinarily does not exceed 15Gy.